

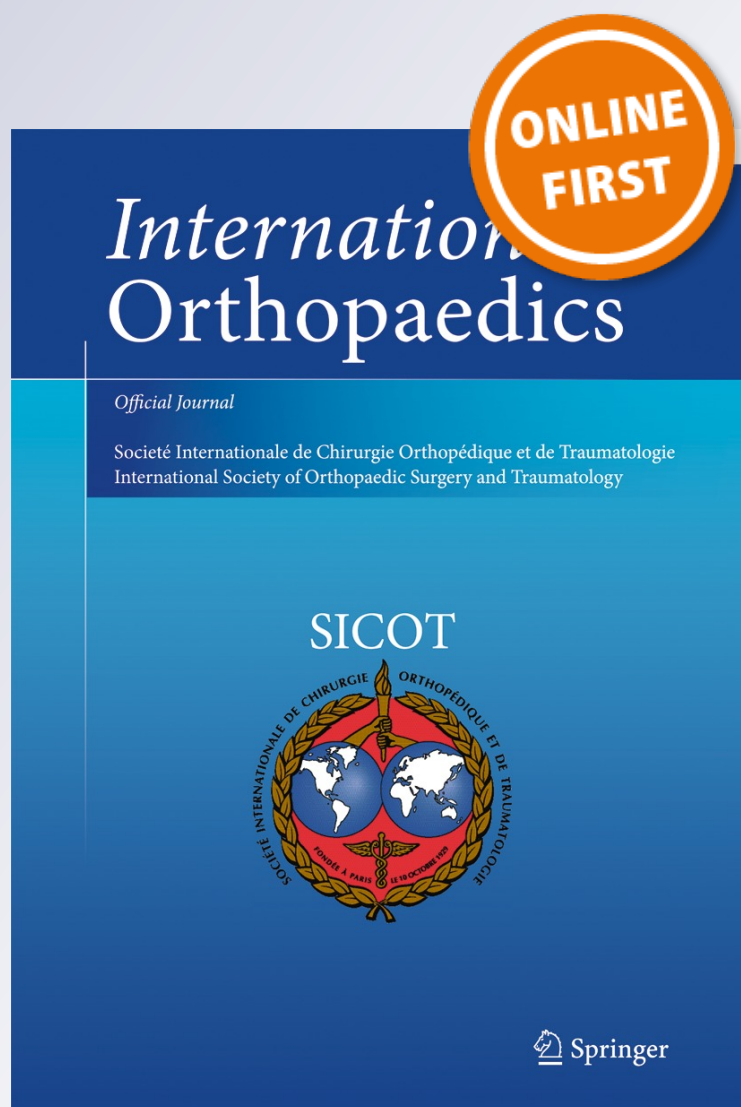
Reversed distal femoral locking plate for failed proximal femoral nail with non-union of proximal femoral fractures

Raju Vaishya, Amit Kumar Agarwal, Nishint Gupta & Vipul Vijay

International Orthopaedics

ISSN 0341-2695

International Orthopaedics (SICOT)
DOI 10.1007/s00264-015-3002-5



Your article is protected by copyright and all rights are held exclusively by SICOT aisbl. This e-offprint is for personal use only and shall not be self-archived in electronic repositories. If you wish to self-archive your article, please use the accepted manuscript version for posting on your own website. You may further deposit the accepted manuscript version in any repository, provided it is only made publicly available 12 months after official publication or later and provided acknowledgement is given to the original source of publication and a link is inserted to the published article on Springer's website. The link must be accompanied by the following text: "The final publication is available at link.springer.com".

Reversed distal femoral locking plate for failed proximal femoral nail with non-union of proximal femoral fractures

Raju Vaishya¹ · Amit Kumar Agarwal¹ · Nishint Gupta¹ · Vipul Vijay¹

Received: 10 July 2015 / Accepted: 14 September 2015
© SICOT aisbl 2015

Abstract

Introduction Failure of proximal femoral fracture managed by proximal femoral nail (PFN) leads to a very difficult situation to handle with conventional techniques, and reversed distal femoral locking compression plate (DF-LCP) is of great benefit in these selective cases.

Methods Twelve patients with ununited proximal femoral fractures including subtrochanteric fractures with a failed PFN implant were included in the study. All patients with periprosthetic fractures and fractures treated by implants other than PFN were excluded from this study.

Result All fractures went into union in an average time of nine months and 15 days with no implant failures. The mean time of re-osteosynthesis after the primary index surgery of PFN was one year eight months. Mean surgical time of re-osteosynthesis was 110 minutes, and average blood loss during surgery was 550 ml.

Discussion The PFM is one of the most commonly used implant for unstable proximal femur fractures. The use of PFN is technically demanding and is associated with high failure rates. Although dynamic compression screw (DCS), proximal femoral locking plate (PF-LCP) and other implants can be used in these failed situations, they are associated with a high

complication rate. The reversed DF-LCP is a rescue implant for these complex situations. Apart from anatomical and biomechanical advantages, there are several other clinical benefits of using DF-LCP.

Conclusion We conclude that DF-LCP is a potential and safe implant of choice for the management of nonunion associated with failed PFN. It may be considered an implant of choice as rescue from such a complex situation. It offers several anatomical, biomechanical and clinical advantages over other available conventional implants.

Keywords Nonunion fracture · Proximal femur · Distal femoral locking plate · Re-osteosynthesis

Introduction

Despite the advancement of several fixation devices, treatment of unstable pertrochanteric fractures and subtrochanteric fractures of the femur remains a challenge [1]. Until the introduction of intramedullary nails (IM), these unstable pertrochanteric fractures were mostly treated with a sliding hip screw system, which was associated with high failure rates [2, 3]. To overcome the problems associated with the sliding hip screw fixation system, the proximal femoral nail (PFN) was introduced in 1997 by AO/ASIF [4, 5]. It combined the features of a femoral IM with hip screws to provide rotational stability of the proximal fracture fragment along with locking at the distal end. However, the use of PFN is technically demanding, and the margin of error is low. Failure to achieve precise reduction of fractured fragments and faulty insertion of this nail is often responsible for the failure of osteosynthesis [6] and non-union. It leaves behind a complex situation to deal with due to the disturbed anatomy of the proximal femur and poor bone stock left for fracture fixation by other implants

✉ Amit Kumar Agarwal
amitorthopgi@yahoo.co.in

Raju Vaishya
raju.vaishya@gmail.com

Nishint Gupta
nishintgupta@gmail.com

Vipul Vijay
dr_vipulvijay@yahoo.com

¹ Department of Orthopaedics, Indraprastha Apollo Hospital, Sarita Vihar, Mathura Road, New Delhi, India 110076

during re-osteosynthesis. Conventional implants used for proximal femoral fracture fixation, such as the dynamic hip screw (DHS), dynamic condylar screw (DCS), PFN, 950°-angle blade plate etc., may not be able to fix these complex and ununited fractures. Hence, there is a need to devise a suitable implant to address this complex situation after a failed PFN. The proximal femoral locking compression plate (AO, Synthes) was introduced recently to deal with such fractures and failed conditions but has been reported to be associated with varus collapse of the fracture and screw breakage due to high axial bending forces, with its high failure rate of up to 27 % [7]. We present our experience with reversed anatomical distal femoral locking compression plate (DF-LCP) for unstable and ununited proximal femur fracture following a failed PFN.

Materials and methods

We had operated upon 12 patients who had a failed PFN and ununited fractures using a reverse DF-LCP (i.e. a right-side plate for a left proximal femoral fracture) classified using the AO/ASIF system [8]. We only included patients with ununited proximal femoral fractures (A2.2 –A3.3), including subtrochanteric fractures with a failed PFN implant. All patients with periprosthetic fractures and fractures treated with implants other than PFN were excluded. Patients were primarily assessed clinically and radiologically for limb shortening, fracture union and implant failure.

Surgical technique

Surgery was performed with the patient in either a lateral decubitus or a supine position on a traction table. In lateral decubitus, anteroposterior (AP) view was taken by rotating the C-arm at 90° and the lateral view by both gently rotating the hip and adjusting the C-arm; in the supine position, the C-arm was positioned in between the two limbs [9]. The failed or broken implants were first removed (distal and proximal screws and then the nail) and the ununited proximal femoral fracture was freshened up and fixed using a reverse DF-LCP. In three cases, varus deformity of the proximal fragment was corrected using a Schanz pin in the femoral neck as a “joystick” [10]. We used a DF-LCP in a reversed position to fix the proximal femoral fracture fragments (Fig. 1) employing a minimally invasive technique, which allowed extra periosteal introduction with minimal damage to soft tissues. The broad end of the plate allowed a sufficient number of 5-mm locking screws to be placed in the proximal femoral fragment in order to optimise adequate fixation. The shaft of the plate allowed fixation with both locking and nonlocking cortical screws, which provided the flexibility to achieve plate-to-bone opposition as well as axial compression or angular stability. A sufficiently

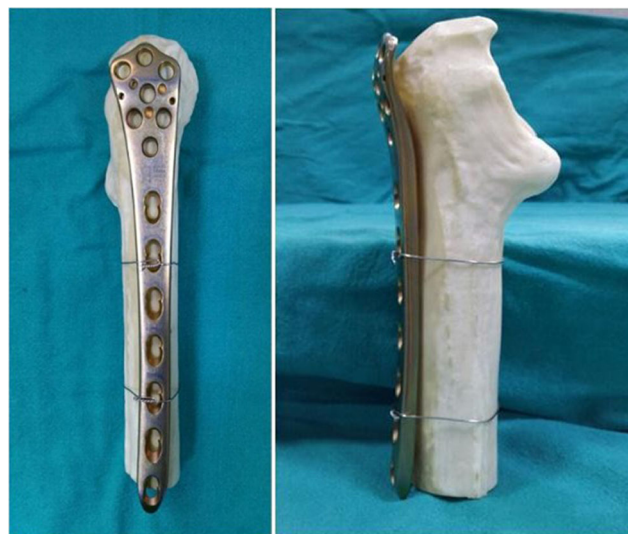

Fig. 1 Anatomical positioning of distal femoral locking compression plate (DF-LCP) in a reverse pattern over proximal femur (front and lateral views)

long plate was used in all cases to allow at least eight to ten cortices to be fixed distal to the fracture.

These patients were mobilised non-weight bearing using walking aids (crutches, frame, walker) two days post-operatively after removal of drains from the surgical site. Hip and knee movements were allowed and encouraged. Weight bearing was gradually increased depending upon union progression on serial radiographs during follow-up, which lasted until a sound union was achieved on radiographs.

Results

There 12 patients (seven men, five women) with an average age of 64.6 (range 37–85) years. Mean time of re-osteosynthesis after the primary index surgery of PFN was one year three months to two years nine months (average 1 year 8 months). All 12 cases had established nonunion of their fractures (Table 1) with implant failure (loosening, breakage, screw cutout) of PFN (Table 2). Mean surgical time of re-osteosynthesis was 110 (range 90–150) min. In all patients, fracture fragments were first freshened and then fixed with a reversed DF-LCP after proper reduction of the fracture fragments. Corticocancellous bone grafts from the contralateral iliac crest were harvested simultaneously by another surgical team and used at the fracture site in all cases. Stability and implant positioning of the construct was checked intra-operatively using an image intensifier and checked post-operatively by X-ray (Figs. 2 and 3). Average blood loss during surgery was 550 (range 320–870) ml. No postoperative splinting was required in any of these cases. The average duration of follow-up was 13 months 41 days (range 12–23 months). We achieved

Table 1 Study demographics

Case no.	Sex	Age (years)	Reason for failure	Union status	Mean time of re-osteosynthesis (months)	Surgery duration (min)	Blood loss (ml)	Bone graft	Average follow-up (months)	Preop shortening (cm)	Postop shortening (cm)	Status of union at last follow-up	Average union time (months)	Complication
1	M	55	Screw cutout	Nonunion	15	100	750	Done	12	3.6	1.5	United	10	Nil
2	M	57	Screw cutout	Nonunion	22	120	870	Done	16	5	2	United	14	Wound dehiscence
3	F	61	Broken neck screw	Nonunion	18	90	600	Done	12	4	1.6	United	8	Nil
4	M	37	Nail breakage	Nonunion	33	105	350	Done	13	3.2	1.3	United	7	Nil
5	F	63	Screw cutout	Nonunion	18	110	650	Done	22	5	1.5	United	12	Nil
6	F	72	Screw cutout	Nonunion	24	120	410	Done	12	4.2	2	United	9	Nil
7	M	85	Broken neck screw	Nonunion	20	150	500	Done	12	4.5	1.5	United	9	Nil
8	F	59	Nail breakage	Nonunion	18	100	400	Done	12	6.5	5.1	United	9	Nil
9	M	72	Screw cutout	Nonunion	15	90	320	Done	12	3.6	1.5	United	8	Nil
10	F	67	Broken neck screw	Nonunion	24	110	500	Done	12	4	2	United	10	Nil
11	M	72	Screw cutout	Nonunion	15	130	650	Done	14	5	1.4	United	9	Nil
12	M	76	Nail breakage	Nonunion	18	95	600	Done	12	4.4	1.5	United	9	Nil
Mean		64.6 years			20 (1 year 8 months)	110 min.	550 (ml)		13.41	4.416	1.9		9.5	

Table 2 Patterns of proximal femoral nail failure

Pattern of failure	No. cases
1) Screw cutout	7
a) Z effect	5
b) Reverse Z effect	2
2) Broken screw	3
3) Broken nail	2

union in all cases with a mean time to radiographic union of nine months and 15 days (7–14 months) (Figs. 4 and 5). None of the DF-LCP implants showed failure on follow-up radiographs. Femoral shortening was improved from an average of 4.4 (range 3.2–6.5) cm preoperatively to 1.9 (range 1.3–5.1) cm post-operatively. No neurovascular complications were observed after the surgical procedure. One case had wound dehiscence and minor surgical-site infection, which was managed successfully by wound debridement and secondary suturing.

Discussion

Unstable pertrochanteric and subtrochanteric fractures are often seen in geriatric individuals due to the high prevalence of osteoporosis in this age group [11], whereas in younger patients, this type of injury is usually caused by high-energy trauma. Fixation of these fractures can be achieved with various modalities, such as PFN, DCS and 90°-angle blade plate [12], but these methods are often associated with complications such as nonunion, shortening, varus collapse, loss of fixation, implant loosening and

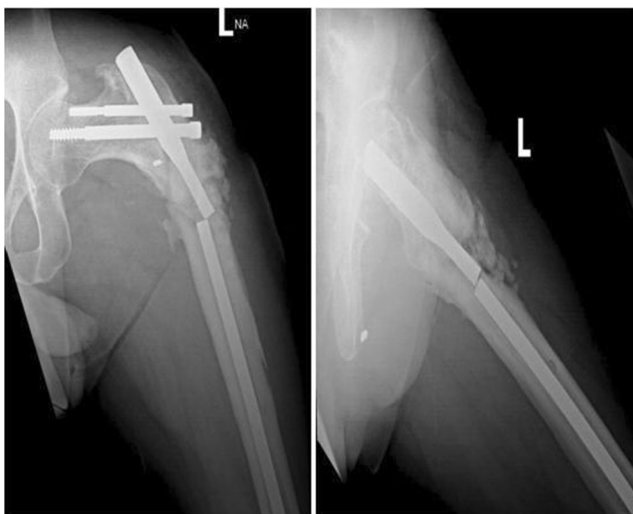

Fig. 2 Anteroposterior (AP) and lateral radiographs of case 4 showing broken proximal femoral nail (PFN) at the subtrochanteric region, with nonunion of the fracture site

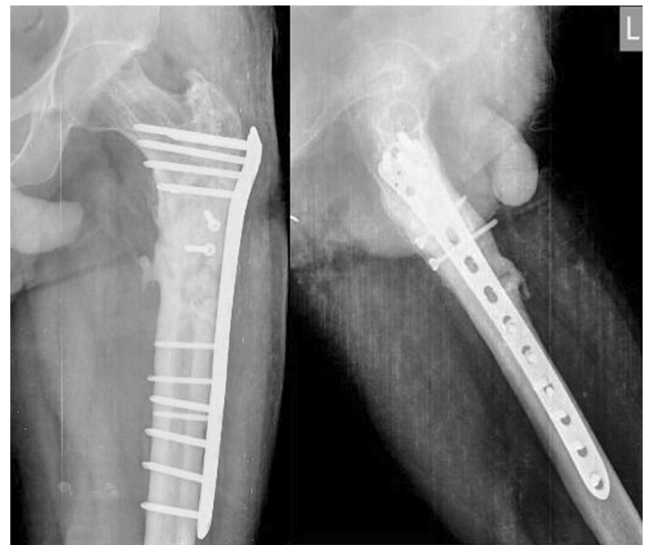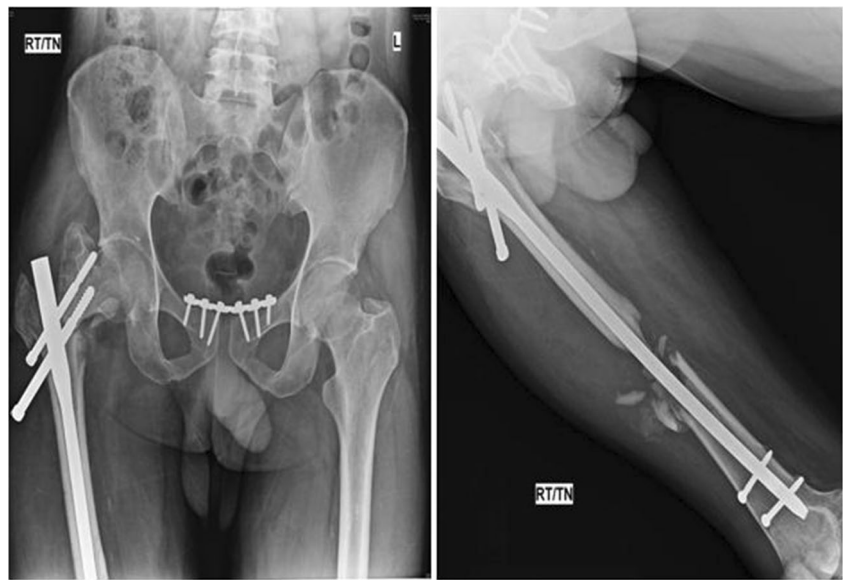


Fig. 3 Thirteen months post-operative anteroposterior (AP) and lateral radiographs of case 4 showing union of subtrochanteric fracture treated with reversed DF-LCP and bone graft

implant breakage. Fixation failure and nonunion in subtrochanteric fractures are typically high and are reported with an incidence of up to 28 % [13]. This is common due to various factors, such as weak, osteoporotic bone, thick cortical bone with scarce blood supply in the subtrochanteric region and biomechanical factors such as high varus stress on weight bearing at the fracture site, which ultimately lead to implant breakage and nonunion. Surgical factors such as poor reduction, wrong nail-entry site and improper positioning of screws leads to screw breakage; screw backout and varus collapse also contribute to failure [14, 15].

One of the most commonly used implants for unstable proximal femur fractures is PFN, which allow rotational stability of the proximal fracture fragment through proximal neck screws. However, use of the PFN is technically demanding and requires high technical expertise, precise reduction, correct entry site, proper positioning of neck screws, failure of which may lead to deficient osteosynthesis and nonunion. The various studies have reported high re-operation rate of 4 % to 28 % with PFN done primarily in unstable proximal femur fractures [16]. In our experience the complication rate of PFN done primarily in unstable proximal femur fractures is approximately 10 % and DF-LCP has turned out to be a good option in these failed cases. In our study, we found three main pattern of failure of PFN (Figs. 6 and 7) in the form of neck-screw cutout (lateral migration of proximal screws) due to the “Z” [17] or reverse “Z” effect, broken nail in subtrochanteric region and broken neck screws (Table 2). Cutout of the neck screw or lateral migration of the proximal screw shows a “Z” effect phenomenon in which the superior screw penetrates the femoral head or pelvis while the inferior screw migrates

Fig. 4 Anteroposterior (AP) and lateral radiographs of case 1 showing failed proximal femoral nail (PFN) with lateral displacement of proximal screws, varus collapse and nonunion at both proximal and distal fracture sites



laterally, which leads to varus collapse of the fracture [18]. The reverse “Z” effect phenomenon occurs due to lateral sliding of the superior screw while the inferior screw remain impacted to the nail [4].

Causes of nonunion could be due to interfragmentary motion due to failure of rigid fixation, interposition of fibrous tissue at the fracture site, malposition of bony fragments by inappropriate reduction or fracture comminution [19]. A variety of implants has been used to fix proximal femoral nonunion. The DCS is a good alternative for failed pertrochanteric fractures but requires considerable technical expertise and leads to hampered periosteal blood supply due to excessive stripping in an already failed fracture with poor biological environment and bone stock [20]. The proximal femoral LCP (PF-LCP; AO Synthes) was introduced recently to deal with such fractures and failed conditions. It is, however, associated with varus collapse of the fracture and screw breakage due to high axial bending forces. Lee et al. reported a high PF-LCP failure rate of up to 27 %, with screw loosening being most common in their study of 26 cases [7].

We have had good outcomes after using reversed DF-LCP for complex proximal femoral fractures with failed PFN and nonunion. Some studies have shown that IMs have limitations in managing fractures types more severe than 31A2.2 [21, 22]. In these cases, a reversed DF-LCP plate was successfully used. In our experience, severe lateral wall comminution is one of the main indication for using a DF-LCP as a primary mode of fixation. A large displaced greater trochanteric fragment may be considered a relative indication due to difficulty in finding the correct entry point if a PFN is being used. In this study, we achieved union in all 12 ununited fractures with the use of reversed DF-LCP and bone grafting. Furthermore, stability of this construct allowed better rehabilitation, appropriate correction of limb-length discrepancy and minimal complications. This partial restoration of length was achieved by correcting varus deformity at the fracture site.

We believe that the DF-LCP is anatomically suitable for the proximal femur using a plate from the contralateral side in a reverse pattern [23]. The head of the plate consists of five threaded 5.0-mm peripheral screw holes that accept locking

Fig. 5 Twelve months' post-operative anteroposterior (AP) and lateral radiograph of case 1 showing fracture union with good callus

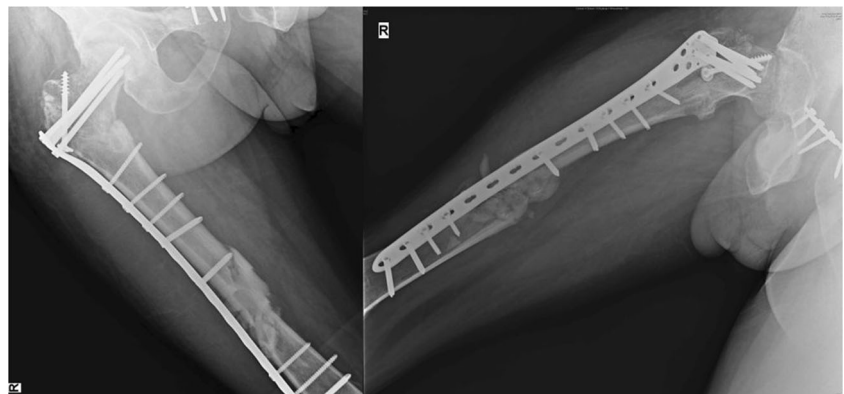
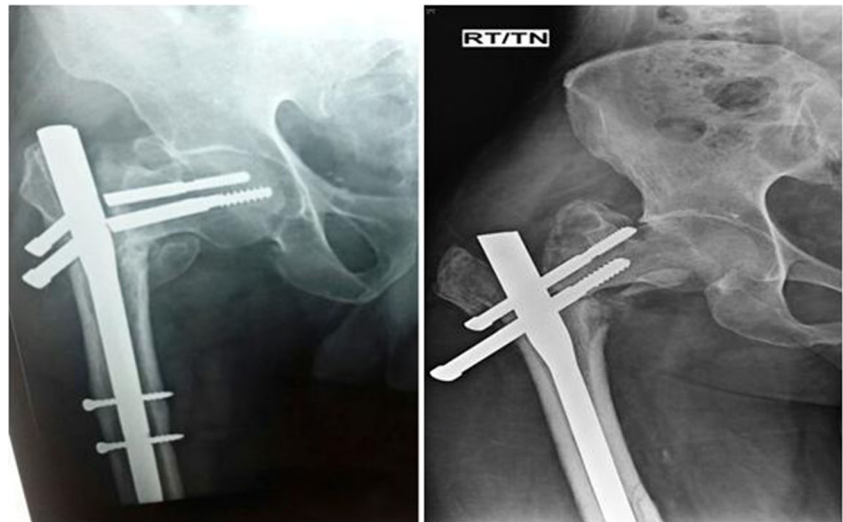


Fig. 6 Broken neck screws of the proximal femoral nail (PFN) (case 3); screw cutout (“Z” effect) (case 1)



screws. The central 7.3-mm screw has an angle of 95° to the plate shaft. The shaft has Combi holes that combine a dynamic compression unit (DCU) hole with a locking screw hole, allowing insertion of standard bicortical screws or a locked screw. Studies have shown that DF-LCP bears more maximal axial load than the DCS by 34 % and of an IM by 13 %, thus advocating its biomechanical advantage. Apart from anatomical and biomechanical advantages, there are several other clinical benefits of using DF-LCP (Table 3) for proximal femoral nonunion, especially after a failed PFN. It has the advantage of multiple screw purchase in the proximal femur and permits the use of minimally invasive surgical techniques in selected cases. Moreover, it is easily available in all setups and can be fixed to the proximal femur even with the retained femoral implant. The locking system of plate and screws improves the stability of construct in an osteoporotic bone that allows early rehabilitation. DF-LCP can be used for

periprosthetic fractures of the hip, as well. It causes less damage to the traumatised bone and soft tissue after failed PFN and is relatively affordable compared with other implants.

Based on our experience and good outcomes, we propose that DF-LCP is a safe as a potential implant of choice for managing nonunion associated with failed PFN. It may be considered an rescue implant of choice in such a complex situation. We are, however, aware that a DF-LCP was not designed for use in proximal femoral fractures. We had used it in selected cases, since it adapts so well to the contour of the proximal femur and provides excellent fixation of complex fractures where other implants are not feasible. Further clinical and biomechanical studies are required to advocate its routine use for all proximal femoral fractures. We believe that due to the background of success using implant, more dedicated implants for fixation of complex fractures of the proximal femur will be available in the near future.

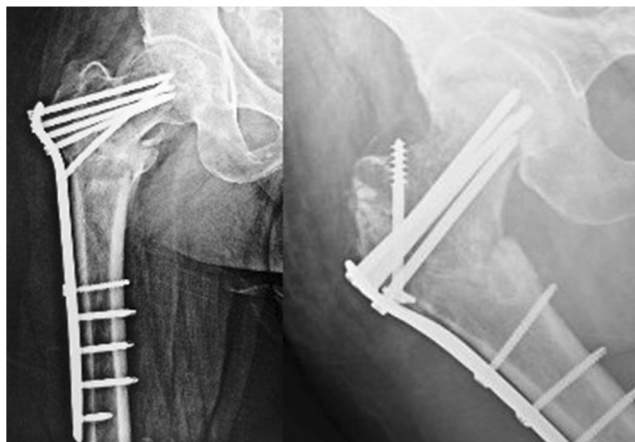


Fig. 7 Anteroposterior (AP) radiograph of cases 3 and 1 showing fracture fixation with a reversed distal femoral locking compression plate (DF-LCP) 12 months post-operatively

Table 3 Clinical advantages of the reversed distal femoral locking compression plate (DF-LCP)

Serial no.	Advantages of reverse DF-LCP in failed proximal femoral fractures after proximal femoral nail
1	Easy availability in all setups
2	Multiple screw fixations in proximal femur
3	Permits the use of minimally invasive surgical techniques
4	Can be fixed to proximal femur even with retained implant in the femur
5	Provide a stable construct which allow early rehabilitation
6	Can be used in periprosthetic fractures of the hip
7	Cost effective
8	Locking system of plate and screws improves stability of construct in osteoporotic bone
9	Less damage to traumatised bone and soft tissue after failed PFN

Compliance with Ethical Standards

Conflict of interest The author(s) declare that they have no competing interests.

References

- Schipper IB, Steyerberg EW, Castelein RM et al (2004) Treatment of unstable trochanteric fractures: randomized comparison of the gamma nail and the proximal femoral nail. *J Bone Joint Surg (Br)* 86(1):86–94
- Simpson AH, Varty K, Dodd CA (1989) Sliding hip screws: modes of failure. *Injury* 20:227–231
- Davis TR, Sher JL, Horsman A et al (1990) Intertrochanteric femoral fractures: mechanical failure after internal fixation. *J Bone Joint Surg (Br)* 72(1):26–31
- Boldin C, Seibert FJ, Fankhauser F et al (2003) The proximal femoral nail (PFN)—a minimal invasive treatment of unstable proximal femoral fractures. A prospective study of 55 patients with a follow-up of 15 months. *Acta Orthop Scand* 74(1):53–58
- Simmermacher RKJ, Bosch AM, Van der Werken C (1999) The AO/ASIF-proximal femoral nail (PFN): a new device for the treatment of unstable proximal femoral fractures. *Injury* 30:327–332
- Kanthimathi B, Narayanan VL (2012) Early complications in proximal femoral nailing done for treatment of subtrochanteric fractures. *Malays Orthop J* 6(1):25–9
- Lee WT, Murphy D, Kagda FH et al (2014) Proximal femoral locking compression plate for proximal femoral fractures. *J Orthop Surg (Hong Kong)* 22:287–293
- Newey ML, Ricketts D, Roberts L (1993) The AO classification of long bone fractures: an early study of its use in clinical practice. *Injury* 24(5):309–12
- Ehlinger M, Brinkert D, Besse J et al (2011) Reversed anatomic distal femur locking plate for periprosthetic hip fracture fixation. *Orthop Traumatol: Surg Res* 97:560–564
- Pape HC, Tarkin IS (2009) Intraoperative reduction techniques for difficult femoral fractures. *J Orthop Trauma* 23(5):S6–11
- Cummings SR, Melton LJ (2002) Epidemiology and outcomes of osteoporotic fractures. *Lancet* 359:1761–1767
- Tencer AF, Johnson KD, Johnston D et al (1984) A biomechanical comparison of various methods of stabilization of subtrochanteric fractures of the femur. *J Orthop Res* 2:297–305
- Kang SH, Han SK, Kim YS et al (2013) Treatment of subtrochanteric nonunion of the femur: whether to leave or to exchange the previous hardware. *Acta Orthop Traumatol Turc* 47(2): 91–95
- Bredbenner TL, Snyder SA, Mazloomi FR et al (2005) Subtrochanteric fixation stability depends on discrete fracture surface points. *Clin Orthop Relat Res* 432:217–225
- Parker MJ, Dutta BK, Sivaji C et al (1997) Subtrochanteric fractures of the femur. *Injury* 28:91–95
- Zhou F, Zhang ZS, Yang H et al (2012) Less invasive stabilization system (LISS) versus proximal femoral nail anti-rotation (PFNA) in treating proximal femoral fractures: a prospective randomized study. *J Orthop Trauma* 26:155–162
- Tyllianakis M, Panagopoulos A et al (2004) Treatment of extracapsular hip fractures with the proximal femoral nail (PFN): long-term results in 45 patients. *Acta Orthop Belg* 70:444–454
- Werner-Tutschku W, Lajtai G, Schmiedhuber G et al (2002) Intra- und perioperative Komplikationen bei der Stabilisierung von per- und subtrochantären Femurfrakturen mittels PFN. *Unfallchirurg* 105:881–885
- De Vries JS, Kloen P, Borens O (2006) Treatment of subtrochanteric nonunions. *Injury* 37:203–211
- Sanders R, Regazzoni P (1989) Treatment of subtrochanteric femur fractures using the dynamic condylar screw. *J Orthop Trauma* 3(3): 206–13
- Sahin S, Ertürer E, Öztürk I et al (2010) Radiographic and functional results of osteosynthesis using the proximal femoral nail anti-rotation (PFNA) in the treatment of unstable intertrochanteric femoral fractures. *Acta Orthop Traumatol Turc* 44(2):127–34
- Simmermacher RKJ, Ljungqvist J, Bail H et al (2008) The new proximal femoral nail anti-rotation (PFNA) in daily practice—results of a multicentre clinical study. *Injury* 39:932–939
- Haq RU, Manhas V, Pankaj A et al (2014) Proximal femoral nails compared with reverse distal femoral locking plates in intertrochanteric fractures with a compromised lateral wall; a randomized controlled trial. *Int Orthop* 38(7):1443–1449