

A RARE CASE OF CHARCOT ELBOW

Raju Vaishya* and Ajay Pal Singh**

*Senior Consultant, **Senior Registrar, Department of Orthopaedics & Joint Replacement Surgery, Indraprastha Apollo Hospitals, Sarita Vihar, New Delhi 110 076, India.

Correspondence to: Dr Raju Vaishya, Senior Consultant, Department of Orthopaedics & Joint Replacement Surgery, Indraprastha Apollo Hospitals, Sarita Vihar, New Delhi 110 076, India.

Charcot's neuropathic joint of elbow is a rare clinical entity. Arthrodesis of the deranged joint is an important treatment option, although it is usually considered difficult to achieve, even surgically.

Key words: Charcot (Neuropathic) joint, Syringomyelia, Elbow arthrodesis.

INTRODUCTION

DEVELOPMENT of a neuropathic (Charcot's) joint in the elbow due to syringomyelia is a rare condition and there are very few reports available in the literature highlighting this entity. We report a case of Charcot elbow following syrinx formation due to tuberculosis. The patient was successfully managed with arthrodesis. To our knowledge this has not been reported in English language literature.

Case Report

A 46-year-old man visited outpatient department with complaints of progressively increasing weakness and instability of left upper limb for two years. He was unable to use left upper limb for activities of daily living.

On examination he had swollen, unstable, painless right elbow with weakness in hand. Active flexion was possible from 25 to 100 degrees with palpable and audible crepitation. Range of supination and pronation was severely restricted. There was weakness of the interosseous muscles and digital flexors of the ipsilateral hand. A sensory examination revealed loss of touch sensation in the area of ulnar nerve distribution. Radiographs of left elbow showed destruction of joint with collapsed distal humeral articular surface and subluxed radial head with bone fragments lying in the joint space with heterotopic ossification in the adjacent tissue (*Fig. 1*). At the time of presentation to us he had residual spastic paraplegia and was wheel chair bound.

The patient had tuberculosis dorsal spine from D2- D4 and he took ATT for one complete year followed by anterolateral decompression of dorsal spine at a tertiary institute seven years back. Three years back he complained

of weakness of lower limbs and was diagnosed of cervicodorsal syrinx C5-D3 (*Fig.2*). He was explained about the prognosis and treatment options of syrinx and patient refused for any kind of surgical intervention for cervicodorsal syrinx.

Infection was ruled out. Blood investigations were within normal limits. CT guided aspiration of elbow joint was done and fluid was investigated for Gram stain, AFB stain and culture and PCR for tuberculosis. All these came out to be negative.

We discussed the treatment options, both conservative and surgical with patient. The patient was keen to have a stable elbow. He was informed that failure of surgical treatment may occur.

Through posterior approach we performed ulnar nerve decompression and anterior transposition with arthrodesis of elbow joint. The ulnar nerve was markedly displaced to lateral side (*Fig.3*). Radial head was excised. Articular margins of humerus and ulna were freshened and a prebent 12 holes locking plate (AO, Synthes) was applied with elbow in functional position. Ulnar nerve was transposed anteriorly and submuscularly. Tissue was sent for gram staining, AFB stain and culture which came out to be negative. After a follow up of one year arthrodesis showed good union with regression of ulnar nerve symptoms.

DISCUSSION

Neuropathic arthropathy of the elbow is a rare entity, with few cases reported in the literature. In a series of ninety one patients with neuropathic arthropathy, Brower and Allman identified only five with involvement of the

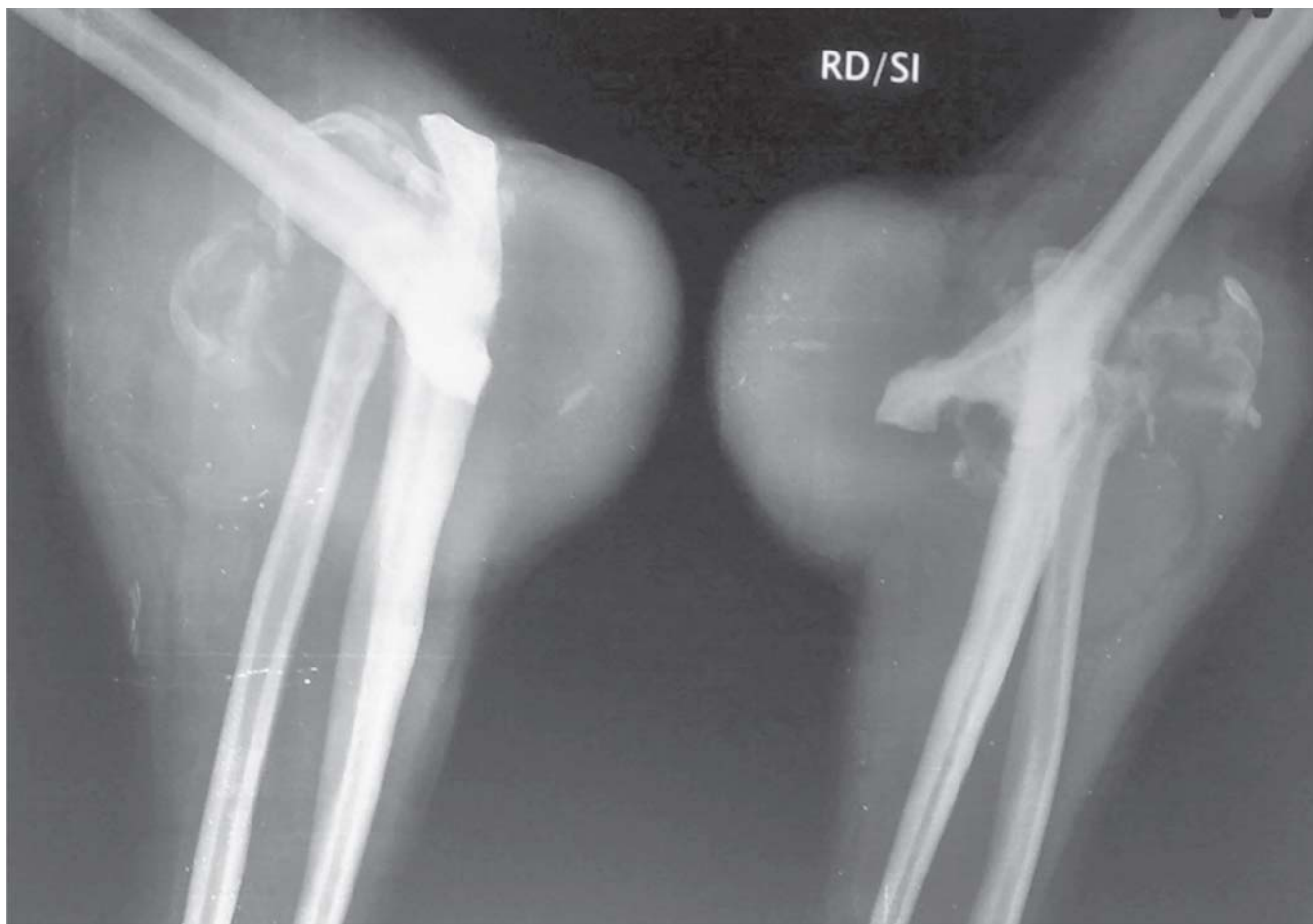

Fig.1. Pre-operative X-ray showing asymmetric and severe destruction of elbow joint.

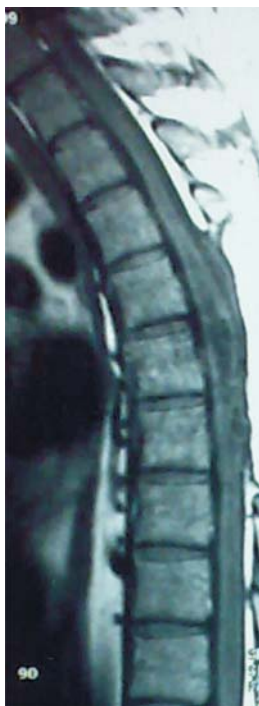

Fig.2. MRI image showing extensive syrinx involving cervico-dorsal cord.

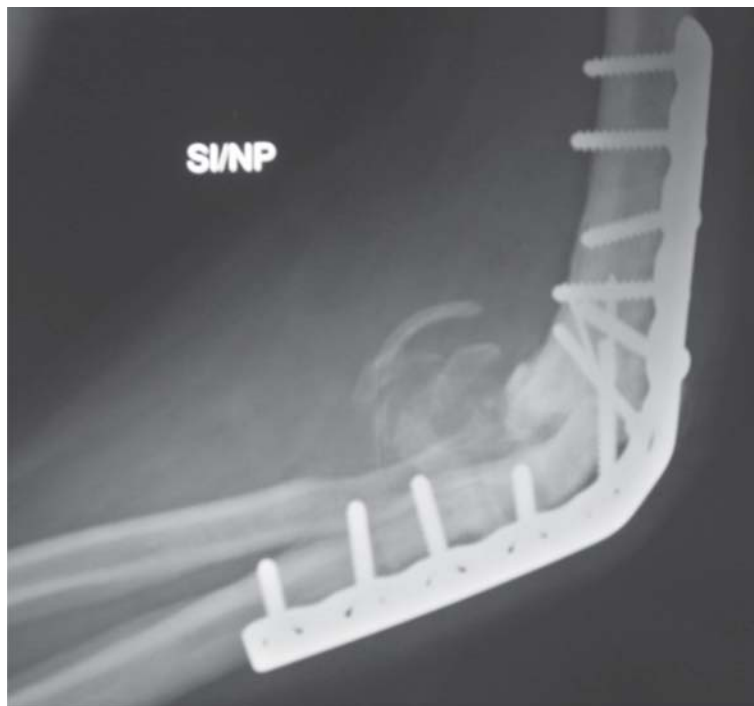


Fig.3. Post -operative X-ray showing elbow fusion.

elbow [1]. Floyd, *et al.* in a series of thirty-nine patients, reported that three had elbow involvement. Eichenholtz noted only three neuropathic elbows among his series of ninety-four joints. There are only few reports and series in the English-language literature that focus specifically on neuropathic arthropathy of the elbow [2]. Neuropathic arthropathy of the elbow in association with syringomyelia is described in very few case reports [3,4].

Two main theories have been put forward for pathogenesis of neuropathic joints. As per the neurovascular theory initial damage to the joint is a result of damage to the autonomic nerves and subsequent disruption of the normal neurovascular reflexes around the joint. This results in hyperaemia and activation of osteoclasts. The resulting bone resorption makes the joint prone to pathological fractures. Alternatively, the loss of protective somatic muscular reflexes can lead to repetitive trauma and ultimately to joint destruction ('neurotraumatic theory'). Syringomyelia is a chronic, progressive, degenerative disorder of the spinal cord, characterized by longitudinal cavitations (syrinx) containing cerebrospinal fluid (CSF) localized in the grey substance. The disorder is commonly associated with type I Arnold–Chiari malformation. Syringomyelia is due to chronic pressure on the spinal cord and in our case it was the sequela of healed tuberculosis of the cord due to myelomalacia.

The association of ulnar nerve injury and neuropathic arthropathy of the elbow has been described in several reports. Ulnar neuropathy is most likely due to distortion of the cubital tunnel as a result of elbow deformity and instability [2]. Our patient underwent decompression and transposition of ulnar nerve ulnar nerve has recovered fully.

In general, surgical intervention in neuropathic joint is not recommended, as it is thought to be associated with unpredictable outcomes [6]. Failure of arthroplasty in neuropathic elbow is due to lack of protective pain sensation and reflexes, the presence of osteopenic bone and the weakness of the surrounding ligaments and muscular tissues. Kwon, *et al* did a total elbow replacement in neuropathic elbow and it culminated in infection and resection arthroplasty has to be done eighteen months later [6].

Most reports describing the management of neuropathic arthropathy have referred to the lower limb, where it is far more common. Arthrodesis is often deemed the best method of treatment, and successful arthrodesis of the foot and knee has been described [7]. Arthrodesis is difficult in elbow, much more in a neuropathic joint. The available literature uses non operative modalities including physical rehabilitation and functional bracing for neuropathic elbow [2,5]. The reason suggested in all series is good patient satisfaction and acceptance of instability. Our patient wanted a stable elbow and opted for arthrodesis. We choose internal fixation for arthrodesing the joint. Locking plate made the procedure easy. After a follow up of one year patient has stable elbow and he can do most of his ADL.

We have presented a case of neuropathic elbow due to syringomyelia following tuberculosis spine. Our case is unique in respect of its etiology as well as treatment. We recommend ruling out infection in such cases before proceeding for surgical treatment and locking plate as the implant of choice for internal fixation.

REFERENCES

1. Brower AC, Allman RM. Pathogenesis of the neurotrophic joint: neurotraumatic vs. neurovascular. *Radiology*. 1981; 139: 349-354 and *J Bone Joint Surg Am*. 2001; 83: 839-844.
2. Carl A Deirmengian, Sang-Gil P Lee, Jesse B Jupiter. Neuropathic Arthropathy of the Elbow: A Report of Five Cases. *J Bone Joint Surg (Am)* 2001; 83-A(6): 839-844.
3. Satoshi Nozawa, Kei Miyamoto, Hirofumi Nishimoto, Yasumichi Sakaguchi, *et al.* Charcot joint in the elbow associated with syringomyelia. *Orthopedics*; 2003; 26, 7.
4. Peter Ruetten, Jos Stuyck, Philippe Debeer. Neuropathic arthropathy of the shoulder and elbow associated with syringomyelia: A report of 3 cases. *Acta Orthop. Belg*, 2007, 73, 525-529.
5. Burcu Yanik AE, Safiye Tuncer AE, Bu"lent Sec, kin. Neuropathic arthropathy caused by Arnold–Chiari malformation with syringomyelia. *Rheumatol Int* 2004; 24: 238-241.
6. Young W Kwon, Bernard F, Morrey M, Rochester. Neuropathic elbow arthropathy: A review of six cases. *J Shoulder Elbow Surg* 2006;15:378-382.
7. Stevens JC. Neurotrophic arthritis. *In: Morrey BF, (ed).* The elbow and its disorders. Philadelphia: Saunders; 1993; 803.