

A CASE OF CHRONIC PANCREATITIS DUE TO HYPER PARATHYROIDISM

Rakesh Kumar

Senior Consultant, Department of Internal Medicine, Indraprastha Apollo Hospitals,
24 Sanchar Vihar, C-58/4, Sector-62, Noida, India.

E-mail: drkumarrakesh@gmail.com, drakeshkumar12@yahoo.com

Chronic pancreatitis is the progressive and permanent destruction of the pancreas resulting in exocrine and endocrine insufficiency and, often, chronic disabling pain. The etiology is multifactorial. 60 to 70% of patients with chronic pancreatitis have a long history of heavy consumption of alcohol before the onset of clinically apparent disease. Primary hyperparathyroidism is a rare cause of chronic pancreatitis and there is paucity of data on this interesting association. The relationship of cause and effect between the two diseases has been debated.

We present here a case of a 42-year-old non-alcoholic man, diagnosed to be suffering from chronic calcific pancreatitis, the cause of which was found to be hypercalcemia due to a solitary parathyroid adenoma.

Key words: Chronic pancreatitis, Hypercalcemia, Primary hyperparathyroidism.

INTRODUCTION

Chronic calcifying/calcific pancreatitis (CCP) is a special form of chronic pancreatitis that tends to calcify or is associated with pancreatic lithiasis. Pancreatic lithiasis refers either to true stones in the duct system of the pancreas called pancreatic calculi or to false stones due to calcification of the parenchyma. Alcoholic calcific pancreatitis (ACP) is the commonest type of chronic pancreatitis seen in the western world, while in the tropics there is a distinct nonalcoholic type of chronic pancreatitis of uncertain etiology, tropical calcific pancreatitis (TCP), which is far more common.

CASE REPORT

A forty two year-old gentleman from Gwalior presented with recurrent episodes of pain and bloating of upper abdomen since 1½ years and pain in the left loin since 1week. The patient had suffered from an attack of acute pancreatitis in January 2008 (?cause). Thereafter, he had continued to have exacerbations of upper abdominal pain every 2-3 months and was hospitalized elsewhere each time, kept nil orally and treated with IV fluids, antibiotics and analgesics. In between the attacks, he would be on regular pancreatic enzyme preparations and intermittent analgesics. Endo-scopic Retrograde Cholangiopancreatography (ERCP) done in August 2008 was normal. A contrast enhanced CT of the abdomen done just prior to admission to our hospital in June 2009 was suggestive of calcification in head region of pancreas with dilated Pancreatic Duct (PD).

The patient's past history was significant for an episode of renal colic in 2004, for which Extracorporeal Shock Wave Lithotripsy (ESWL) had been done elsewhere. He was a non-smoker and non-alcoholic and had no significant family history or occupational history.

Per abdominal examination revealed only mild tenderness in epigastrium with no rebound tenderness or palpable lump, swelling or organomegaly. Other general and systemic examination was normal.

Serum amylase and lipase levels were high. A CECT abdomen was suggestive of features of chronic calcific pancreatitis (*Fig.1*). Magnetic Retrograde Cholangiopancreatography (MRCP) confirmed the findings of CT abdomen. ERCP was undertaken twice to cannulate the dilated PD and relieve the obstruction; however, the guidewire could not be manipulated beyond the stone and the PD could not be cannulated. The patient was then subjected to 3 sessions of ESWL, during which the stone was seen breaking. In view of the past history of renal stones and present situation of calcification in pancreas, serum calcium levels were done; these were mildly raised at 12.8 mg/dL. Further clinical suspicion for the cause of this led to checking of serum parathormone levels, which were also found to be raised to a level of 115.5ng/dL. Ultrasonographic examination of the neck was normal, while Sestamibi scan and CT scan of the neck for parathyroids was suggestive of a solitary lower left parathyroid adenoma (*Figs. 2 & 3*). The patient was thereafter taken up for parathyroidectomy, HPE of which revealed adenoma (*Fig. 4*). Subsequently, his serum

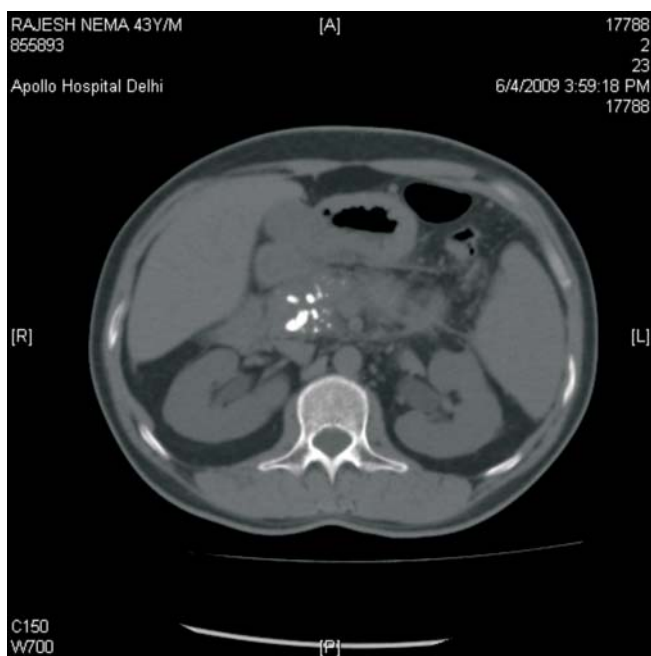


Fig.1. CT abdomen showing chronic calcific pancreatitis.

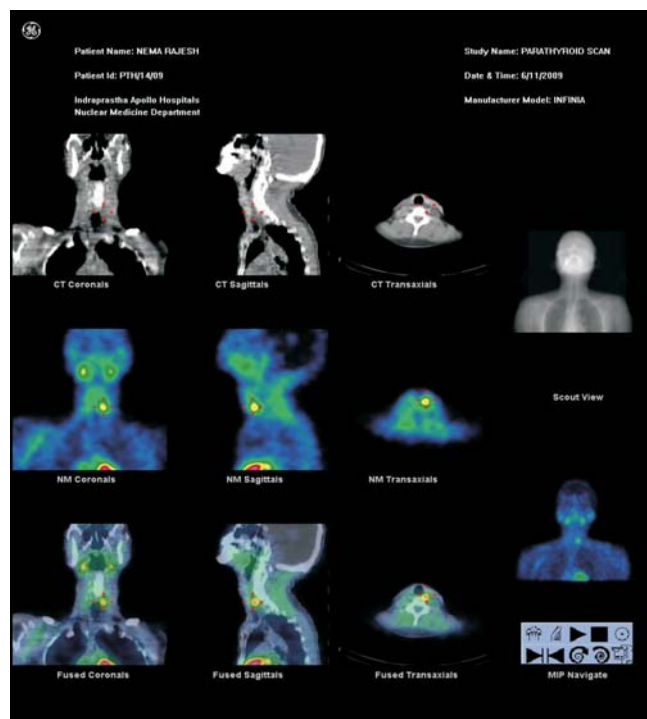


Fig.3. CT of the neck showing left parathyroid adenoma.

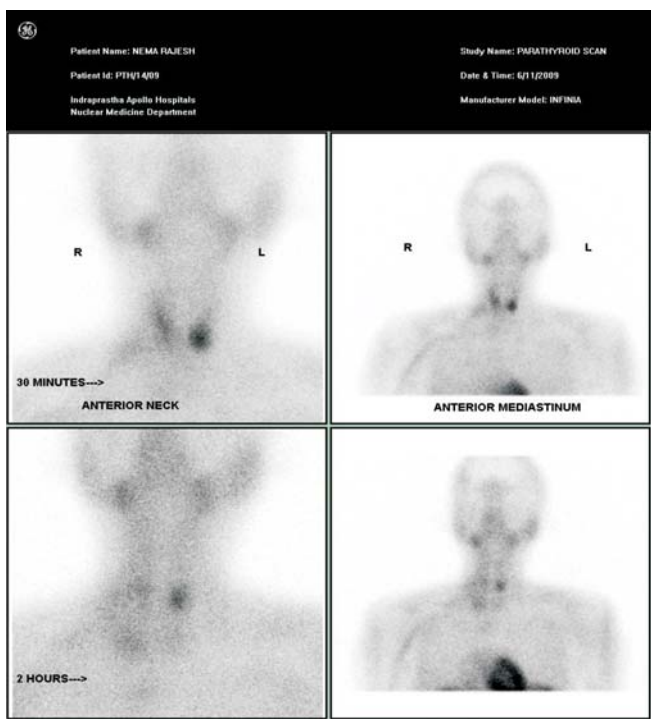


Fig.2. Sestamibi scan showing left parathyroid adenoma.

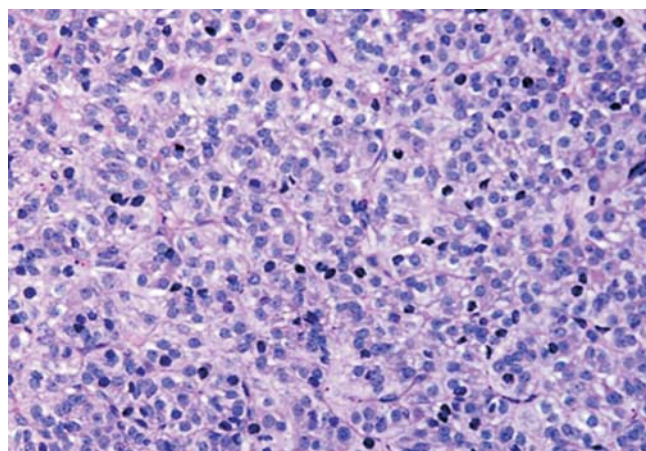


Fig.4. HPE of the resected parathyroid adenoma.

calcium levels normalized and he had considerable reduction in the episodes of exacerbations of chronic pancreatitis, thereby having a relief in the pain.

DISCUSSION

The incidence of chronic pancreatitis has quadrupled

in the past 30 years because of advances in medical imaging and more inclusive definitions. Chronic alcohol use accounts for 70% of the cases of chronic pancreatitis in adults, and most patients have consumed more than 150 g of alcohol per day over 6 to 12 years [1]. Genetic diseases (e.g., cystic fibrosis) and anatomic defects predominate in children. The TIGAR-O (Toxic-metabolic, Idiopathic, Genetic, Autoimmune, Recurrent and severe acute pancreatitis, Obstructive) classification system is based on risk factors for chronic pancreatitis [1].

Primary hyperparathyroidism (PHPT) is a rare cause of chronic pancreatitis. Presence of normal or increased serum calcium in the setting of pancreatitis raises the

suspicion of primary hypercalcemic state as the underlying cause.

Pancreatitis related to PHPT was first reported over 60 years ago [2]. The cause-and-effect relation between the two diseases initially lead to controversies [3]. The pathophysiological theory where pancreatitis was responsible for PHPT has been abandoned. Pancreatitis appears in the literature to be the consequence rather than the cause of PHPT [4]. The healing of pancreatitis after parathyroidectomy favours this hypothesis. The low rate of multiple enlarged parathyroid glands is also an argument for the idea that the disease is primarily parathyroid.

Data from the west suggests an association in upto 7% of cases [5]. Centres from India have reported a prevalence of upto 15.2% [6]. The largest study from India is a recent prospective, nationwide study of 1,086 subjects of chronic pancreatitis carried out by The Indian Pancreatitis Study Group [7]. The results were as follows: Idiopathic pancreatitis was the most common form of pancreatitis ($n=622$; 60.2%) and alcoholic chronic pancreatitis accounted for about a third of the cases ($n=400$; 38.7%). Using well-defined criteria, only 39 (3.8%) cases could be labeled as 'tropical pancreatitis'. The rest ($n=11$; 1.1%) had rare risk factors, including pancreas divisum ($n=4$; 0.4%) and hyperparathyroidism ($n=2$; 0.2%); in addition, one patient each (0.1%) had agenesis of the pancreas, autoimmune pancreatitis, hypertriglyceridemia-related pancreatitis, trauma and microlithiasis.

Chronic pancreatitis due to PHPT has important characteristics in its biochemical and clinical manifestations. When compared to alcohol-related chronic pancreatitis and idiopathic chronic pancreatitis, the incidence of renal colic, nephrolithiasis, and nephrocalcinosis were significantly more common in patients with chronic pancreatitis due to PHPT [6] (as was also true of the case reported). Similarly, bone disease, palpable neck nodule, and psychiatric abnormalities were statistically more common in the latter group. The complications of CP such as steatorrea, diabetes mellitus, pancreatic calcification, and pancreatic pseudocyst were not statistically different across the three groups.

When patients of chronic pancreatitis due to PHPT were compared with PHPT patients without chronic pancreatitis, renal colic, nephrolithiasis, steatorrea, and diabetes mellitus were significantly more common in the former group, whereas bone disease was more common in patients with PHPT without chronic pancreatitis [6].

The mean corrected calcium and mean iPTH levels were significantly higher in patients of chronic pancreatitis due to PHPT, while other biochemical parameters such as serum amylase, serum alkaline phosphatase (ALP), blood sugar, and triglyceride levels were not different from patients with alcohol-related chronic pancreatitis and idiopathic chronic pancreatitis [6].

The issue of the relationship between primary hyperparathyroidism and pancreatitis and its mechanism needs to be clearly resolved. The mechanism of development of pancreatic disease in PHPT is correlated to the hypercalcaemia [8]. Hypercalcaemia per se, in addition to being an independent risk for the precipitation of pancreatic cellular injury, could also augment pancreatic disease in patients with ongoing pancreatic injury because of other causes. The exact cellular mechanism by which hyper-calcaemia causes pancreatic injury in PHPT remains to be elucidated [8].

A classification of the presentation of pancreatic disease in PHPT into four important classes has been suggested [8]:

1. PHPT presenting as acute pancreatitis
2. PHPT presenting as acute recurrent pancreatitis with no evidence of chronic pancreatitis
3. PHPT presenting as chronic pancreatitis with or without pancreatic calcification
4. PHPT complicated by acute pancreatitis in the postoperative period

A review of the literature on the clinical presentation various case series revealed that Class 1 presentation was the most common, occurring in over 44% of patients, underlining the need to check calcium values in all patients presenting with the first episode of pancreatitis. There were no documented reports of patients who developed acute pancreatitis in the postoperative period. In over one-third of the patients the disease was more insidious and presented with evidence of chronic pancreatitis. Parathyroid surgery at this point may not reverse the pancreatic pathology and long-term therapy for exocrine and endocrine pancreatic insufficiency may be required. However, it would be still be prudent to check serum calcium levels in these patients as early parathyroid surgery would prevent associated renal and bone disease.

REFERENCES

1. Nair RJ. Chronic Pancreatitis. *Am Fam Physician* 2007;76:1679-1688.

2. Smith FB. Acute fatal hyperparathyroidism. *Lancet* 1940; 236: 650-651.
3. Bess MA. Hyperparathyroidism and Pancreatitis. Chance or a Causal Association? *JAMA* 1980; 243: 246-247.
4. Carnail B. Pancreatitis and primary hyperparathyroidism: Forty cases. *Aust N Z J Surg* 1998;68: 117-119.
5. Cope O. Pancreatitis, a diagnostic clue to hyperparathyroidism. *Ann Surg* 1957;145: 857-863.
6. Bhadada SK. Chronic pancreatitis in primary hyperparathyroidism: Comparison with alcoholic and idiopathic chronic pancreatitis. *J Gastroenterol Hepatol* 2008; 23: 959-964.
7. Balakrishnan V. Chronic Pancreatitis. A Prospective Nationwide Study of 1,086 Subjects from India. *JOP. J Pancreas (Online)* 2008; 9: 593-600.
8. Jacob JJ. Does hyperparathyroidism cause pancreatitis? A South Indian experience and a review of published work. *ANZ J Surg* 2006; 76: 740-744.